








Case Report



Successful Management of Dermatophytosis in a Desi Short Hair Domestic Kitten

Naresh Mohanraj¹ , Abiramy Prabavathy Arumugam^{2,*} , Vijayalakshmi Padmanaban² , Banoth Sai Nehru¹ , and Vivek Subramanian² 

¹ Student, Rajiv Gandhi Institute of Veterinary Education and Research, Puducherry, India

² Department of Veterinary Clinical Complex, Rajiv Gandhi Institute of Veterinary Education and Research, Kurumbapet, Puducherry, India

* **Corresponding author:** Abiramy Prabavathy Arumugam, Rajiv Gandhi Institute of Veterinary Education and Research, Kurumbapet, Puducherry, India.
Email: abiramy@river.edu.in

ARTICLE INFO

Article History:

Received: 01/07/2023

Revised: 07/08/2023

Accepted: 13/08/2023

Published: 25/09/2022



Keywords:

Dermatophytosis

Endothrix

Itraconazole

Microsporum sp.

Pinna-pedal reflex

Ringworm

ABSTRACT

Introduction: Dermatophytosis is an uncommon fungal infection of hair and skin in the claw. The infection is caused by the invasion of the hair shaft and stratum corneum by Keratophilic fungi. Fungal skin problems in pet animals commonly occur in hot and humid climatic regions. Cats suffer from superficial dermatophytosis despite their licking and self-cleansing behavior.

Case report: A two-month-old female desi-short hair domestic kitten weighing 1.2 kg body weight was presented to Veterinary Clinical Complex, Kurumbapet, India, with a history of crusty patchy alopecic lesions on the rump and paw of the right forelimb for the past week in July 2022. The owner also reported generalized hair loss and scratching. Clinical examination revealed patchy circular dry lesions on the rump and the paw of the right forelimb. No abnormality was detected in the general appearance of the kitten. Behavioral habit was active, appetite and voiding habits were normal, popliteal lymph nodes were palpable, heart rate was 170 beats/minute, respiratory rate was 22 breaths/minute, rectal temperature was 101.8°F, and the conjunctival mucous membrane was pink. The pinna-pedal reflex was negative. Direct microscopy of the skin scraping sample revealed highly positive endothrix spores in the hair shaft. The smear prepared from the culture of the scrapings was stained with Lactophenol Cotton Blue, which confirmed the growth of ligamentous hyphae and mycelium of the dermatophyte, *Microsporum* spp. Hence, the case was diagnosed with superficial dermatophytosis caused by *Microsporum* spp. The kitten was successfully treated with itraconazole syrup (Felintra, Savavet, India) administered at the dosage of 5 mg/kg oral for 2 alternative weeks (every 24 hours for 7 days). Moreover, Cetirizine tablet as a non-sedating medicine and antihistamine which acts selectively on H1-receptor was given orally at the dosage of 2.5 mg/cat for the next 5 days, and liver supportive (Liv.52 syrup which contains herbal extracts) was administered orally at the dosage of 0.5 ml daily to overcome the hepatotoxic effect of anti-fungal drugs. Complete recovery was noticed by the third week of treatment which was the second week of the itraconazole syrup (Felintra, Savavet, India) treatment.

Conclusion: Dermatophytosis in a kitten was diagnosed early and treated promptly with a proper treatment schedule with itraconazole without any untoward effects on the kitten.

1. Introduction

Dermatophytosis or ringworm is a highly contagious and infectious superficial fungal infection of hair, skin, and nails¹. The infection is caused by the invasion of the hair shaft and stratum corneum by keratinophilic fungi². commonly found

causative agents in pet animals are *Microsporum canis*, *Trichophyton mentagrophytes*, and *Microsporum gypseum*³. It is found that over 90% of Feline dermatophytosis worldwide is caused by *Microsporum canis*, infecting both humans and

► Cite this paper as: Mohanraj N, Arumugam AP, Padmanaban V, Nehru BS, Subramanian V. Successful Management of Dermatophytosis in a Desi Short Hair Domestic Kitten. Small Animal Advances. 2023; 2(3): 33-37. DOI: 10.58803/saa.v2i3.15



The Author(s). Published by Rovedar. This is an open-access article distributed under the terms of the Creative Commons Attribution License (<http://creativecommons.org/licenses/by/4.0>), which permits unrestricted use, distribution, and reproduction in any medium, provided the original work is properly cited.

animal species^{3,4}. A survey on dermatophytosis in 292 cats in and around Kolkata indicated a prevalence of 98.02%⁵. Dermatophytosis is most often seen in cats younger than one year old. Pregnant and lactating queens are prone to ringworm infection. Flea and *Cheyletiella* mite infestation in cats is an important risk factor for the spread of dermatophytosis. Feline immunodeficiency virus and feline leukemia virus seropositive status in cats alone might be the predisposing factor for infection⁶. Long-haired pure-breed cats, such as Persian cats, are more commonly affected⁷. Adult female cats and kittens showed a higher incidence of dermatophytosis infection, compared to male cats in Indonesia. As indicated, male cats are at high risk of contracting the disease, compared to female cats⁸.

Direct cat-to-cat transmission of infective spores is one of the principal risk factors and routes of transmission. Cats can be exposed to infective spores through various means, including contact with external parasites or contaminated objects. Airborne transmission is also reported in a field study. The incubation period for the infection typically ranges from 2 to 4 weeks, although evidence suggests that active infection may develop even sooner⁹.

Dermatophytosis, commonly known as ringworm, is a fungal infection that affects the skin, hair, and nails of humans and animals. The disease is caused by dermatophytes, which are fungi that invade the superficial layers of the skin, hair shaft, or follicles, and claws. These fungi can quickly penetrate the host's innate immune defenses, enabling them to infect the keratinous tissues of the body¹⁰. In the case of ringworm in cats, the pathogen spreads through arthrospores, which are released from the infected cat's hair, claws, and skin into the environment, and they create germ tubes to penetrate the stratum corneum and hair when they contact new host skin¹⁰. The invasion occurs more likely in animals with ectoparasites when exposed to higher humidity and micro trauma to skin¹⁰. Clinical signs most commonly appear within 2-4 weeks after exposure, but infected cats shed the infectious spores before clinical signs appear. Spores and infected hairs remain viable in the environment for about 12-18 months. The immune system of host response is mediated by the release of cytokines, neutrophils, and macrophages in the presence of dermatophyte hyphae and arthrospores¹⁰.

A combination of lesions, such as alopecia, papules, scales, crusts, erythema, follicular plugging, hyperpigmentation, pruritus, and nodules, can be seen on the face and ears, progressing toward other parts of the body. Additionally, changes in nail growth and self-induced injury that resemble pyotraumatic lesions can occur. The common diagnostic techniques for identifying dermatophytosis from other skin diseases are dermoscopy, Wood's lamp and fluorescence, direct examination of hair or scale, fungal culture, trichogram, polymerase chain reaction, and biopsy¹¹. Itraconazole is the drug of choice for systemic therapy, and terbinafine would be an alternative treatment³. Recommended topical

treatment is rinsing the body repeatedly with an enilconazole solution or miconazole with or without chlorhexidine. In catteries, intensive decontamination of the environment is important and must be accompanied by the medications³.

Zoonoses and nosocomial infections can be prevented by properly treating infected animals and humans and educating individuals about adequate hygienic and disinfection measures¹².

Only a few efficacy studies have been published for cats on anti-*Microsporum canis* vaccines (prophylactic or therapeutic), and no safe and efficient vaccine is available³. The aim of the current case report was to examine the efficacy of itraconazole syrup (Felintra) in clinical dermatophytosis in a cat.

2. Case report

The present study presented the clinical signs, diagnosis, treatment, and prognosis of dermatophytosis in a kitten. A two-month-old female Desi short hair domestic kitten referred to the Veterinary Clinical Complex, Small Animal Medicine Unit, Rajiv Gandhi Institute of Veterinary Education and Research, Puducherry, India, with a history of dry, circular patchy ringworm-like lesions on the rump and paw of the right forelimb with generalized hair-loss and pruritis. The kitten was neither vaccinated (feline panleukopenia virus, calicivirus, viral rhinotracheitis, feline herpes virus, and rabies) nor dewormed.

The clinical examination revealed circular patchy ringworm-like lesions on the rump (Figure 1) and the tip of the paw (Figure 2) of the right forelimb. Pinna-pedal reflex was negative, and other parameters, such as heart rate was 170 beats/minute, respiratory rate was 22 breaths/minute, rectal Temperature was 101.8°F. Behavioral habit was active, popliteal lymph nodes were palpable, and the conjunctival mucous membrane was pink. Physical examination revealed dry, circular patchy ringworm lesions in the rump region and the paw region of the right fore-limb with generalized alopecia and severe scratching (pruritis) was noticed. A superficial skin scraping was taken in a clean glass slide with liquid paraffin.

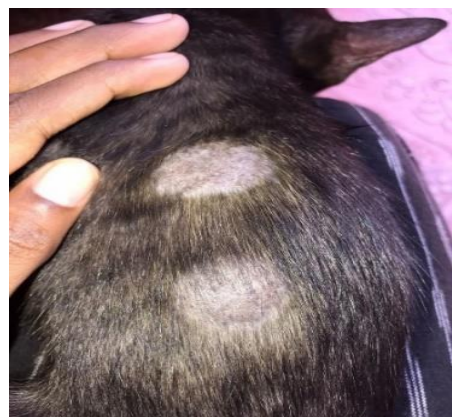

Figure 1. Patchy ringworm skin lesions in a 2-month-old Desi-short hair female kitten

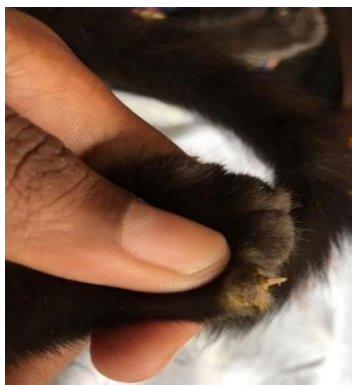


Figure 2. The patchy lesion in the paw region of a 2-month-old Desi-short hair female kitten

Direct microscopic (Olympus, India) examination (10x objective lens) revealed numerous Endothrix (arthrospore) in the hair shaft (Figure 3).

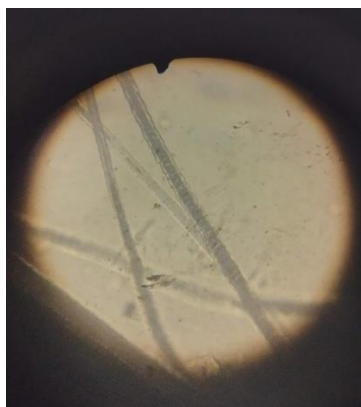

Figure 3. Direct microscopic examination of skin scraping of a 2-month-old Desi-short hair female kitten indicating endothrix, arthrospore

fungal culture is often regarded as the gold standard test for diagnosis. The test was performed with Sabroud Dextrose Agar (SDA) for the early detection of *dermatophyte*⁶. The sample was inoculated in the SDA and incubated at 30°C in a dark room. After 7 days of incubation, white woolly colonies with a yellowish reverse pigment were noticed, which was in line with a previous report¹³ (Figure 4) and then the suspicious colonies were prepared by sticky tape sampling method and stained by Lactophenol Cotton




Figure 4. Skin Scraping sample of a 2-month-old Desi-short hair female kitten inoculated into Sabroud Dextrose Agar on day 7

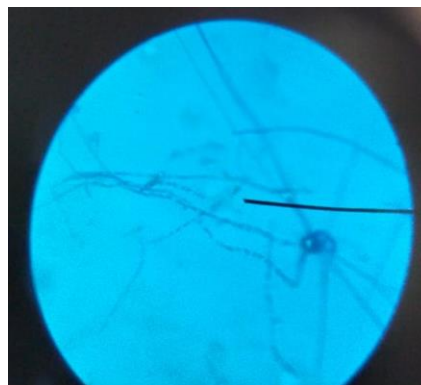


Figure 5. Fungal culture and microscopic examination of a skin scraping sample collected from a 2-month-old Desi-short hair female kitten (Spores, long filamentous hyphae, and mycelium were noticed, LCB staining, 40X)

Blue and examined using a microscope under 40x magnification. As can be seen in Figure 5, there were spores, long filamentous hyphae, and mycelium. Based on the clinical signs, direct microscopical examination, and fungal culture, the skin condition was diagnosed as dermatophytosis caused by *Microsporum* sp.

The kitten was orally administered itraconazole (Syrup Felintra, Savavet, India) at a dosage of 5 mg/kg once a day for 7 days repeated over 2 alternative weeks. The concentration of itraconazole in the syrup was 10 mg/ml. Itraconazole, a systemic anti-fungal agent belonging to the triazole class, exhibits broad-spectrum activity and is notably more potent than ketoconazole and fluconazole. Its mode of action is fungistatic¹⁴. In addition, the cat was prescribed Cetirizine tablets at a dosage of 2.5 mg per cat administered orally for the subsequent 2 days. Cetirizine is non-sedating, and has an action selectively on H1-receptor. Some sources have indicated that cetirizine is a useful nonsteroidal antipruritic/antihistamine agent for cats with allergic and eosinophilic skin disease¹⁵. To provide liver support, a herbal extract-based syrup (syrup Liv.52, India) was prescribed orally at the dosage of 0.5 ml daily as a natural appetite stimulant and hepatoprotective to overcome the hepatotoxic effect of anti-fungal drugs.

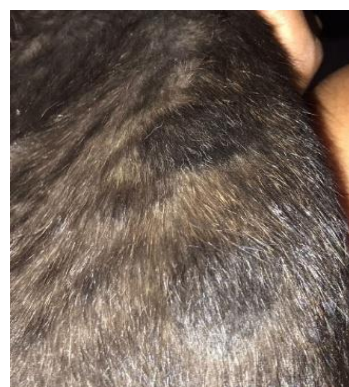

Figure 6. Improvement of a 2-month-old Desi-short hair female Kitten, after the first week of treatment.

Complete recovery was noticed by the second week of the Felintra syrup treatment with normal hair growth in the affected areas, reduced hair loss, and no scratching (Figures 6 and 7).



Figure 7. Complete recovery of a 2-month-old Desi short hair female kitten, after the third week of treatment

3. Discussion

The prevalence of dermatophytosis was 44.36%, 40.43%, and 65.91% in cats, dogs, and humans, respectively, in a study conducted in Iraq¹⁶. The study conducted by Murmu *et al.*¹⁷ has shown the prevalence of dermatophytosis is high in cats (55.5%) when compared to dogs (37.8%) and humans (6.7%). High temperature and humidity play an important role in the development of dermatophytosis infection in hosts. In tropical countries, the prevalence of dermatophytosis in cats is higher due to constant humidity and temperature, than in four-season countries like Turkey⁷. Dermatophytosis is highly contagious in cats and has zoonotic risk⁷. The infected cats act as the disseminators of the fungal infection in their homes, as the finding shows that the fungal species found in their homes and from the fomites are the same as those in infected cats. The incidence of this mycotic zoonosis is higher due to the intimate contact between humans, pets, and fomites. Isolation and proper treatment of the infected animals and humans with adequate hygienic and disinfection measures should be explained by veterinarians to reduce the potential risk of zoonosis¹². As keratinized tissues are affected, dermatophytosis infection in cats appears as superficial dermatosis, multifocal circular patches of alopecia with scaling is the most commonly seen clinical sign noticed in cats, and they sometimes develop nodular dermatophyte lesions like mycetoma, psuedomycetoma, and kerion¹³. Direct examination of the hairs and scales confirms the presence of the infection. Apart from dermoscopy, Wood's Lamp and fluorescence, polymerase chain reaction, skin cytology, skin biopsy, and Fungal culture are considered the gold-standard test for diagnosing dermatophytosis. These are the diagnostic techniques commonly used in diagnosing/differentially diagnosing dermatophytosis from other infections, such as *Malassezia dermatitis*, demodicosis, and pyoderma¹⁸. Systemic anti-fungal therapy prevents the proliferation of the fungal infection⁸. Itraconazole is the drug of choice and terbinafine would be an alternative treatment and is considered to be effective and safe^{3,8}. Itraconazole stops the conversion of lanosterol to ergosterol by inhibiting fungal cytochrome P450 enzyme 14 alpha demethylase, and it is given as an oral formulation at the dosage of 5 mg/kg on a

weekly basis⁸. Cats can also be treated with terbinafine, orally administered at 30-40 mg/kg once daily³. Other drugs, such as Griseofulvin, are effective, but have more adverse effects. Ketoconazole and fluconazole have more side effects and are less effective than the above-mentioned drugs⁸. Recommended topical anti-fungal therapy with rinses/creams or ointments includes Lime sulfur (2-4%), miconazole (2%), and enilconazole (2%), which are effective, and other products found to be terbinafine (1%), thiabendazole (4%), clotrimazole (1%). Care should be taken to prevent the animal from licking them and these procedures should be

carried out in well-ventilated areas⁶. Intensive decontamination of the environment also plays an important role in the eradication of dermatophytosis. Active ingredients, such as 0.2% enilconazole, 1:33 lime sulfur, and 1:100 household chlorine bleach, are active against arthrospores which can be used in shelters or catteries as disinfectants³.

4. Conclusion

Efficient treatment of dermatophytosis relies on a well-defined protocol, particularly when the condition is identified in its early stages. In this specific case, a comprehensive treatment approach was undertaken using itraconazole itraconazole (drug of choice), a broad-spectrum anti-fungal drug that is more potent than ketoconazole, and fluconazole. This was complemented by the administration of cetirizine tablets, functioning as an antihistaminic agent (specific H1 blocker) and a liver supportive syrup (Liv.52), endowed with hepatoprotective qualities and the ability to stimulate natural appetite. This meticulously designed regimen resulted in the kitten's complete recovery from the dermatophytosis, without any adverse effects observed. It is noteworthy that concerns might arise among clinicians about the administration of itraconazole to kittens due to potential side effects and their age. However, the findings from this study strongly recommend the safe utilization of itraconazole syrup for managing dermatophytosis in kittens, devoid of discernible negative impacts.

Declarations

Competing interest

The authors were cooperative and had no dispute in this study.

Authors' contribution

Abiramy Prabavathy Arumugam diagnosed the case, M. Naresh conducted the treatment, Banoth Sai Nehru has done the Fungal culture, and Vijayalakshmi Padmanaban supervised the whole procedure. All authors have carefully read and given the approval of the final version of the article for publication in the present journal.

Funding

The authors didn't receive any type of financial support for Authorship and/ or for Publication of this article.

Availability of data and materials

The authors of this study will send the necessary and related data based on reasonable requests.

Ethical considerations

The manuscript has been read and approved by all the named authors. All authors consented to publish this article and confirm that there is no plagiarised information in the article. All sentences are written originally, and all available data are published in this article.

Acknowledgments

The authors would like to express their special thanks to the Dean, Rajiv Gandhi Institute of Veterinary Education and Research, and The Veterinary Clinical Complex, Puducherry, India, for providing all the facilities and giving permission to publish this article.

References

1. Young A. Ringworm in cats (Dermatophytosis). UCDAVIS veterinary Medicine; Animal Health topics. 2023. Available at: <https://healthtopics.vetmed.ucdavis.edu/health-topics/ringworm-cats-dermatophytosis>
2. Paterson S. Manual of skin diseases of the dog and cat. 2nd ed. Blackwell Publishing; 2008. Available at: <https://go.rovedar.com/5a2>
3. Paryuni AD, Indarjulianto S, and Widyarini S. Dermatophytosis in companion animals: A review. *Vet World*, 2020; 13(6): 1174-1181. DOI: [10.14202/vetworld.2020.1174-1181](https://doi.org/10.14202/vetworld.2020.1174-1181)
4. Frymus T, Gruffydd-Jones T, Grazia Pennisi M, Addie D, Belák S, Boucraut-Baralon C, et al. Dermatophytosis in cats: ABCD guidelines on prevention and management: Clinical review. *J Feline Med Surg*. 2013; 15(7): 598-604. DOI: [10.1177/1098612X13489222](https://doi.org/10.1177/1098612X13489222)
5. Debnath C, Mitra T, Kumar A, and Samanta I. Detection of dermatophytes in healthy companion dogs and cats in eastern India. *Iran J Vet Res*. 2016; 17(1): 20-24. PMID: 27656224
6. Bajwa J. Feline dermatophytosis: Clinical features and diagnostic testing. *Can Vet J*. 2020; 61(11): 1217-1220. PMID: 33149363
7. Zaks FHMd, Airin CM, Nururrozi A, Yanuarono, and Indarjullanto S. A review: The prevalence of dermatophytosis on cats in Indonesia and Turkey. *BIO Web of Conferences*. 2021; 33: 06004.
8. Paryuni AD, Indarjulianto S, Untari T, and Widyarini S. Dermatophytosis in cats: Clinical signs and identification of etiological agent. *Adv Anim Vet Sci*. 11(4): 539-543. DOI: [10.17582/journal.aavs/2023/11.4.539.543](https://doi.org/10.17582/journal.aavs/2023/11.4.539.543)
9. Karen Moriello, Feline Dermatophytosis: Aspects pertinent to disease management in single and multiple cat situations. *J Feline Med Surg*. 2014; 16: 419-431. DOI: [10.1177/1098612X14530215](https://doi.org/10.1177/1098612X14530215)
10. White A. Dermatophytosis in cats. 2021; 31(1). Available at: <https://vetfocus.royalcanin.com/en/scientific/dermatophytosis-in-cats>
11. Moriello KA, Coyner K, Paterson S, and Mignon B. Diagnosis and treatment of dermatophytosis in dogs and cats. *Vet Dermatol*. 2017; 28(3): 266-e68. DOI: [10.1111/vde.12440](https://doi.org/10.1111/vde.12440)
12. Neves JJA, Paulino AO, Vieira RG, Nishida EK, and Coutinho SDA. The presence of dermatophytes in infected pets and their household environment. *Ary Bras Med Vet Zootec*. 2018; 70(6): 1747-1753. DOI: [10.1590/1678-4162-9660](https://doi.org/10.1590/1678-4162-9660)
13. Indarjulianto S, Yanuarono Y, Nururrozi A, Raharjo S, and Ajiguna JC. Combination of systemic and topical treatment for feline dermatophytosis: A case report. *Acta Vet Indonesiana*. 2020; 8(1): 18-23. DOI: [10.29244/avi.8.1.18-23](https://doi.org/10.29244/avi.8.1.18-23)
14. Tripathi KD. Essentials of medical pharmacology. 7th ed. Jaypee Brothers, Medical Publishers Ltd; 2013. DOI: [10.5005/jp/books/12256](https://doi.org/10.5005/jp/books/12256)
15. Griffin JS, Scott DW, Miller WH Jr, and Tranchina MM. An open clinical trial for the efficiency of cetirizine hydrochloride in the management of allergic pruritus in cats. *Can Vet J*. 2012; 53(1): 47-50. PMID: 22753962
16. Jarjees KI, and Aboziad Issa N. First study on molecular epidemiology of dermatophytosis in cats, dogs, and their companions in the Kurdistan region of Iraq. *Vet World*. 2022; 15(12): 2971-2978. DOI: [10.14202/vetworld.2022.2971-2978](https://doi.org/10.14202/vetworld.2022.2971-2978)
17. Murmu S, Debnath C, Pramanik AK, Mitra T, Jana S, Dey S, et al. Detection and characterization of zoonotic dermatophytes from dogs and cats in and around Kolkata. *Vet World*. 2015; 8(9): 1078-1082. DOI: [10.14202/vetworld.2015.1078-1082](https://doi.org/10.14202/vetworld.2015.1078-1082)
18. Moriello K. Dermatophytosis in dogs and cats: A practical guide to diagnosis and treatment. *In Practice*. 2019; 41(4): 138-147. DOI: [10.1136/inp.l1539](https://doi.org/10.1136/inp.l1539)